Mount Sinai Hospital
Sinai Health System
Joseph & Wolf Lebovic Health Complex

Management of Impacted Teeth - II

Dr. Brian Rittenberg DDS, MSc, FRCD(C)
Division Head, Oral and Maxillofacial Surgery
Sinai Health System
and
Crescent Oral Surgery

OBJECTIVES

- REVIEW
  - TECHNIQUES
    - LOWER THIRD MOLARS
    - UPPER THIRD MOLARS
    - CUSPIDS
    - SUPERNUMERARY TEETH
  - ALTERNATIVES TO REMOVAL OF IMPACTED TEETH
    - EXPOSURE/BONDING
    - SURGICAL UPRIGHTING
    - NO TREATMENT
    - PARTIAL EXTRACTION (CORONECTOMY)
  - POST-OPERATIVE CARE

REVIEW

- Indications to remove impacted teeth

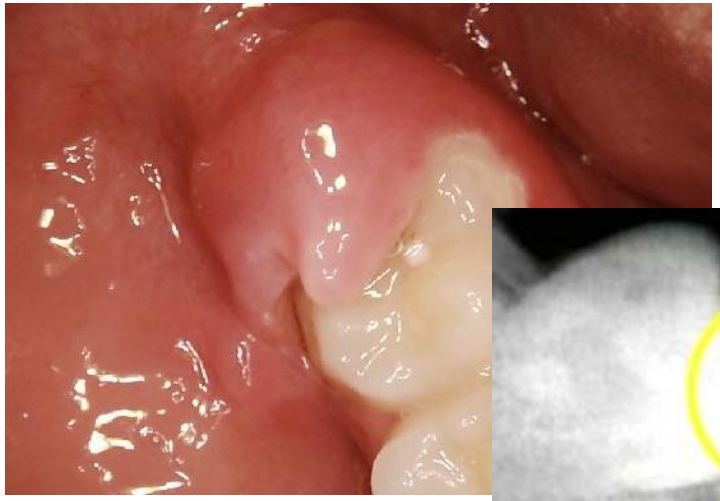

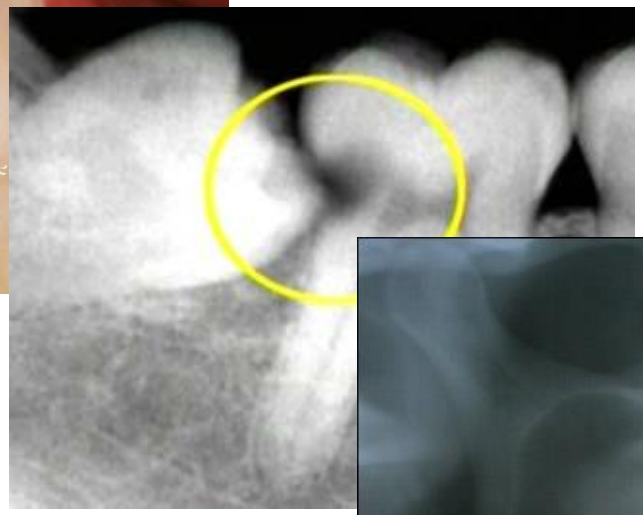

REVIEW

- Informed consent
  - Alternative treatments discussed including no treatment and the potential consequences
  - Risks
  - Normal post-operative sequellae
  - All questions answered

DIAGNOSIS

DIAGNOSIS

- History and Physical
  - Chief complaint and associated history
  - Review of systems / health history
  - Medication list
  - Allergies
  - Anesthetic assessment

DIAGNOSIS

- Health history ***RED FLAGS***

  - **BLEEDING ISSUES**
    - **Congenital**
    - **Acquired**
    - **Medication induced**

  - **IMMUNE SYSTEM COMPROMISE**
    - **Medications**
    - **Systemic (diabetes etc…)**

  - **CARDIAC/RESPIRATORY/RENAL/HEPATIC ISSUES**

DIAGNOSIS

- Clinical exam
  - Complete (do not have tunnel vision)
  - Is tooth / are teeth probe-able
  - Is there acute inflammation
  - Have surrounding teeth been effected

DIAGNOSIS

- Radiographic exam
  - Periapical
  - Occlusal
  - Panorex
  - CT / CBCT

DIAGNOSIS

- Radiographs
  - Must c
    - Entire
    - Relev

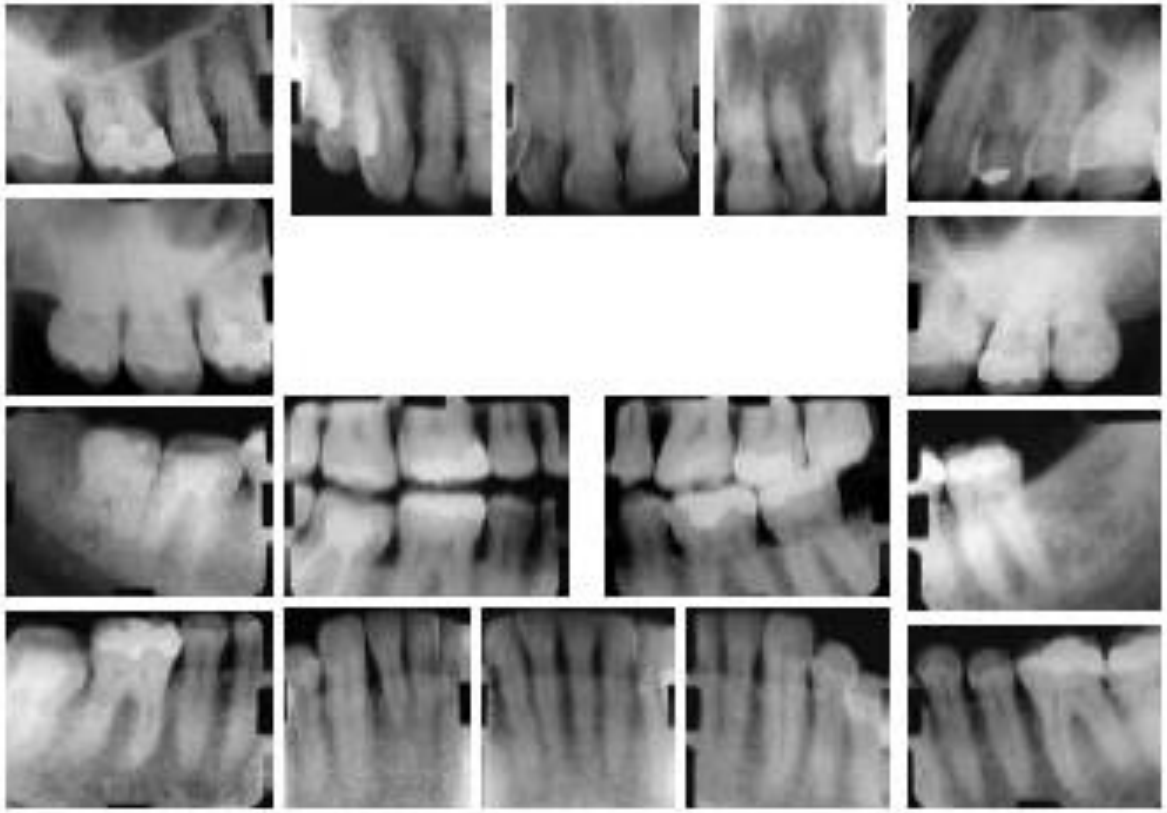

Mount Sinai Hospital
Sinai Health System
Joseph & Wolf Lebovic Health Complex

DIAGNOSIS

- Panorex

Mount Sinai Hospital
Sinai Health System
Joseph & Wolf Lebovic Health Complex

DIAGNOSIS

- CBCT

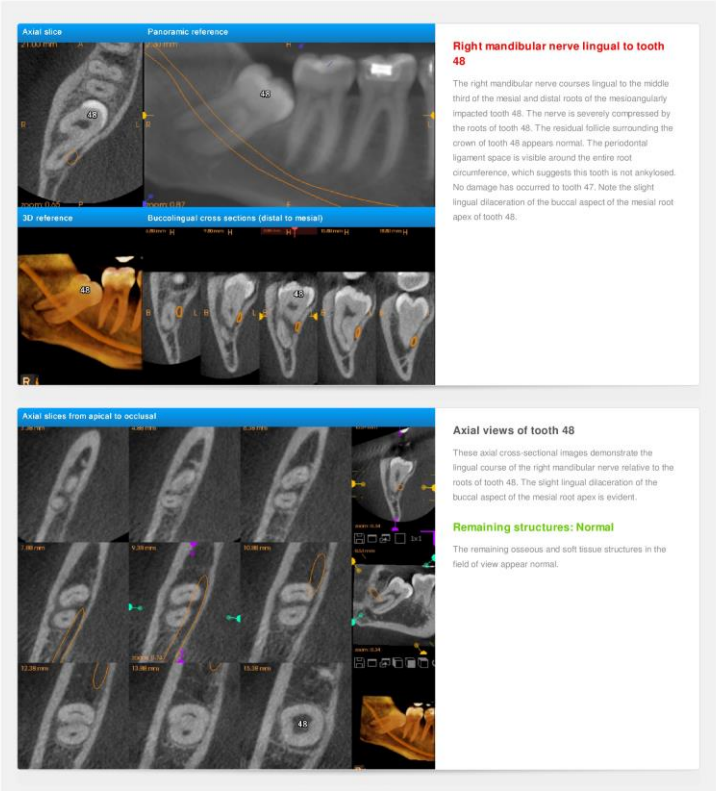

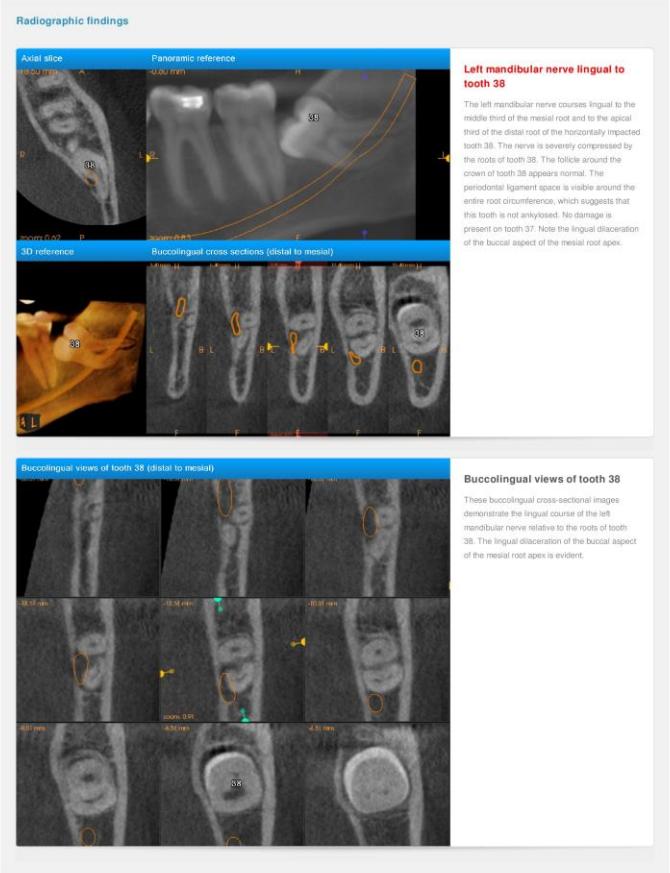

Mount Sinai Hospital
Sinai Health System
Joseph & Wolf Lebovic Health Complex

THIRD MOLARS

IMPACTION CLASSIFICATION

- PELL AND GREGORY
  - Depth and Ramus relationship
- WINTER'S
  - Angulation

WINTER CLASSIFICATION (1926)

- Based on long axis of the impacted tooth relative to the long axis of the second molars
  - VERTICAL
  - MESIOANGULAR
  - DISTOANGULAR
  - BUCCOANGULAR
  - LINUO-ANGULAR
  - INVERTED
  - UNUSUAL

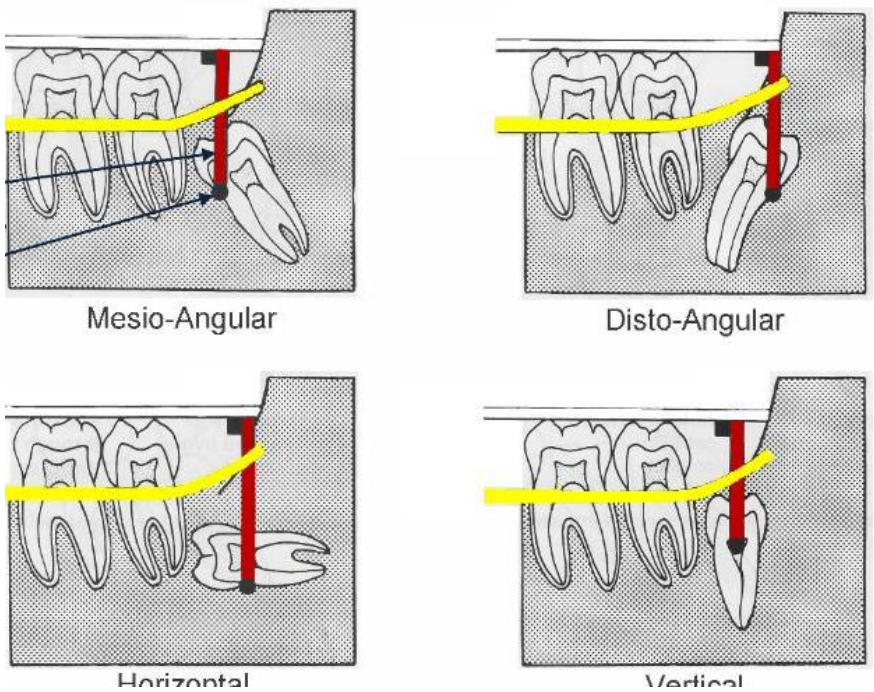

Mount Sinai Hospital
Sinai Health System
Joseph & Wolf Lebovic Health Complex

PELL AND GREGORY CLASSIFICATION

- BASED ON 2 VARIABLES
  - Relationship of impacted tooth to the mandibular ramus
  - Relative depth of the third molar in bone

PELL AND GREGORY CLASSIFICATION

- Class I : There is sufficient space between the ramus and the distal side of the second molar for accommodation of mesiodistal diameter of the crown of the third molar

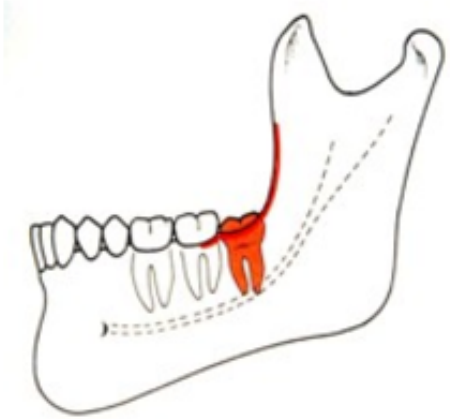

PELL AND GREGORY CLASSIFICATION

CLASS 2

- The space between the ramus and distal side of the second molar is less than the mesiodistal diameter of crown of the second

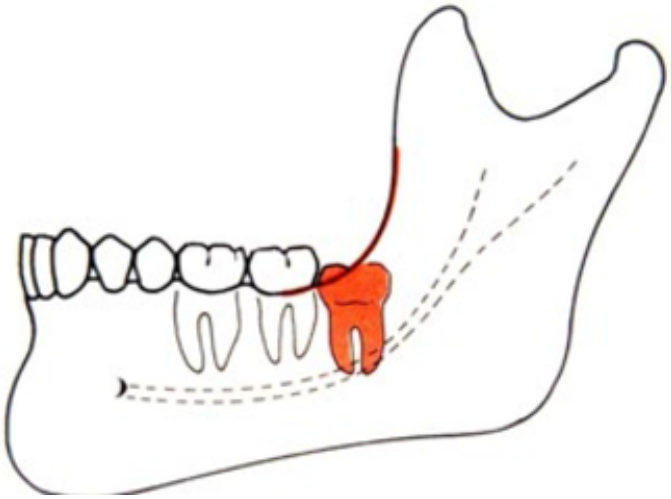

Mount Sinai Hospital
Sinai Health System
Joseph & Wolf Lebovic Health Complex

PELL AND GREGORY CLASSIFICATION

- Class III : All or most of the third molar is located within the ramus

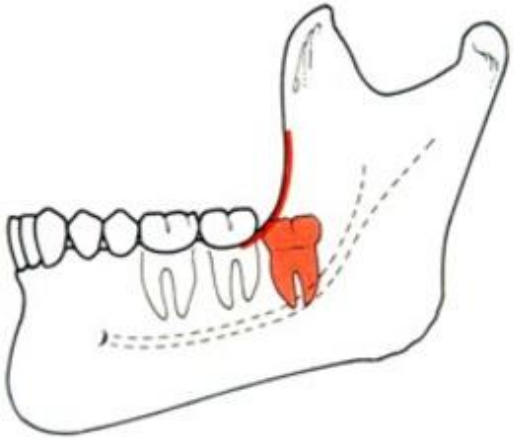

Mount Sinai Hospital
Sinai Health System
Joseph & Wolf Lebovic Health Complex

PELL AND GREGORY CLASSIFICATION

- Position A: The highest portion of the tooth is on a level with or above the occlusal line

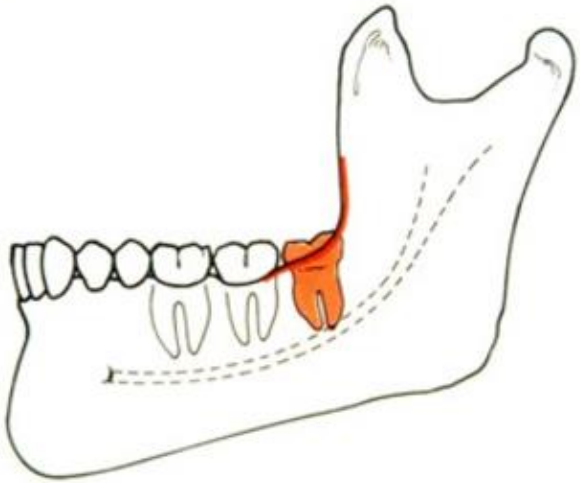

Mount Sinai Hospital
Sinai Health System
Joseph & Wolf Lebovic Health Complex

PELL AND GREGORY CLASSIFICATION

- Position B: The highest portion of the tooth is below the occlusal plane, but above the cervical line of the second

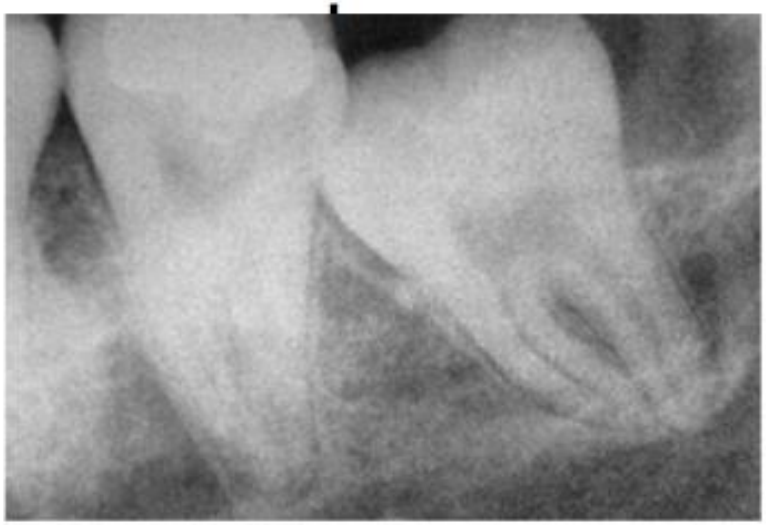

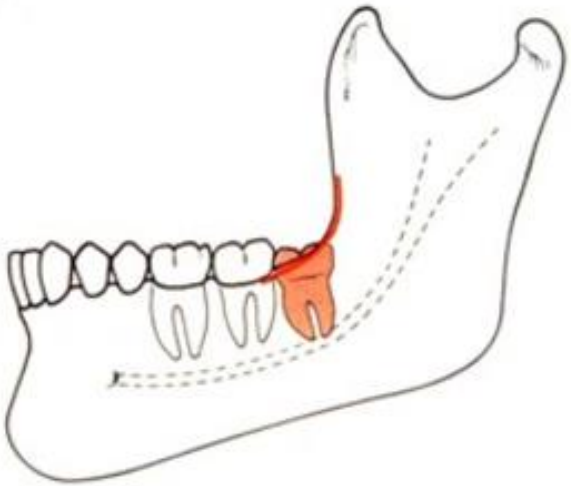

Mount Sinai Hospital
Sinai Health System
Joseph & Wolf Lebovic Health Complex

PELL AND GREGORY CLASSIFICATION

- Position C: The highest portion of the tooth is below the cervical line of the second molar

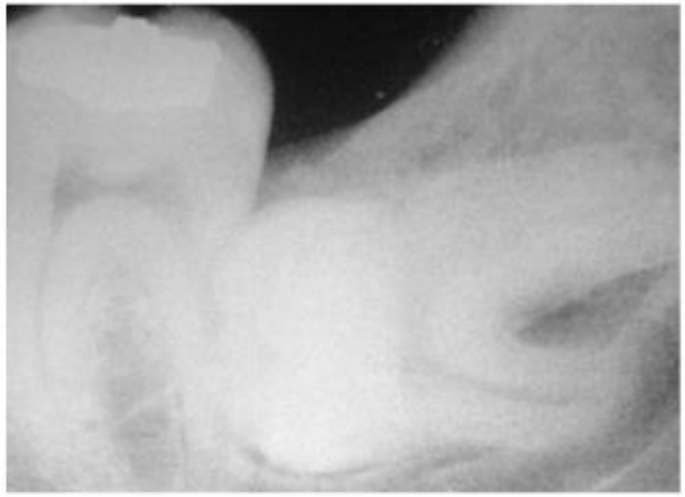

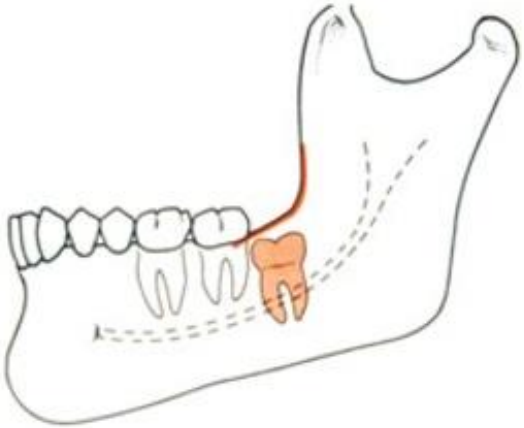

IMPACTION CLASSIFICATION

Difficulty Index for the Removal of Impacted *Mandibular* 3rd Molars, as described by **Pederson**

Classification	Value
Spatial relationship	
Mesioangular	1
Horizontal/transverse	2
Vertical	3
Distoangular	4
Depth	
Level A: high occlusal level	1
Level B: medium occlusal level	2
Level C: deep occlusal level	3
Ramus relationship/space available	
Class 1: sufficient space	1
Class 2: reduced space	2
Class 3: no space	3
Difficulty index	
Very difficult	7–10
Moderately difficult	5–6*
Slightly difficult	3–4

*In the original index, moderately difficult was graded as 5–7.

Mount Sinai Hospital
Sinai Health System
Joseph & Wolf Lebovic Health Complex

IMPACTION CLASSIFICATION

- MAXILLARY THIRD MOLAR IMPACTION DIFFICULTY BASED ON
  - DEPTH
  - ANGULATION
  - PROXIMITY TO MAXILLARY SINUS

SURGICAL TECHNIQUE

- GAIN ADEQUATE ACCESS THROUGH A PROPERLY DESIGNED FLAP
- REMOVE BONE – JUDICIOUSLY
- SECTION THE TOOTH AND DELIVER IT WITH ELEVATORS
- DEBRIDE AND IRRIGATE SOCKET
- SUTURE

SURGICAL TECHNIQUE

- FLAP DESIGN
  - Envelope (distal release)
  - Full thickness
  - Caution – Lingual Nerve

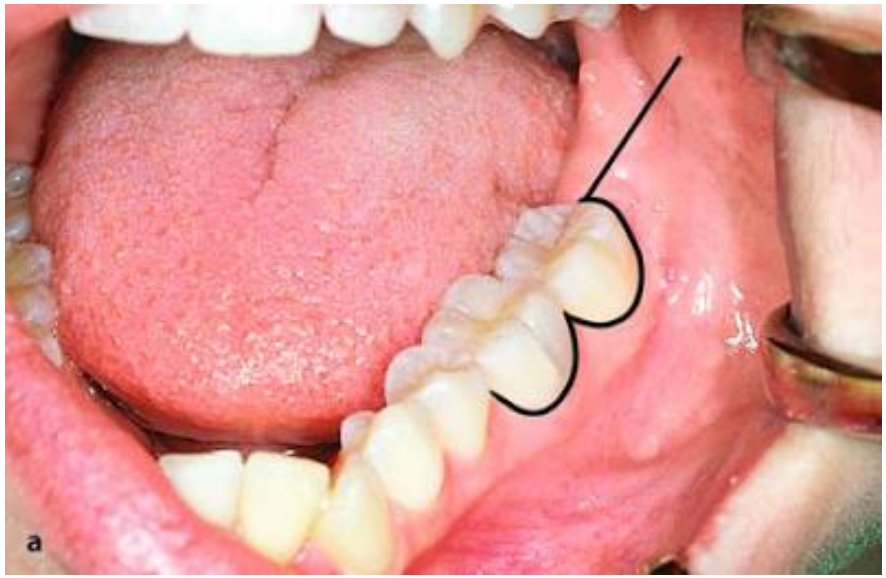

SURGICAL TECHNIQUE

- Lingual nerve and flap design
  - Generally lies r ... est in the retromolar regi
  - Anomalous pa ... olar region
    - **DISTAL RELEA ... ECTED**

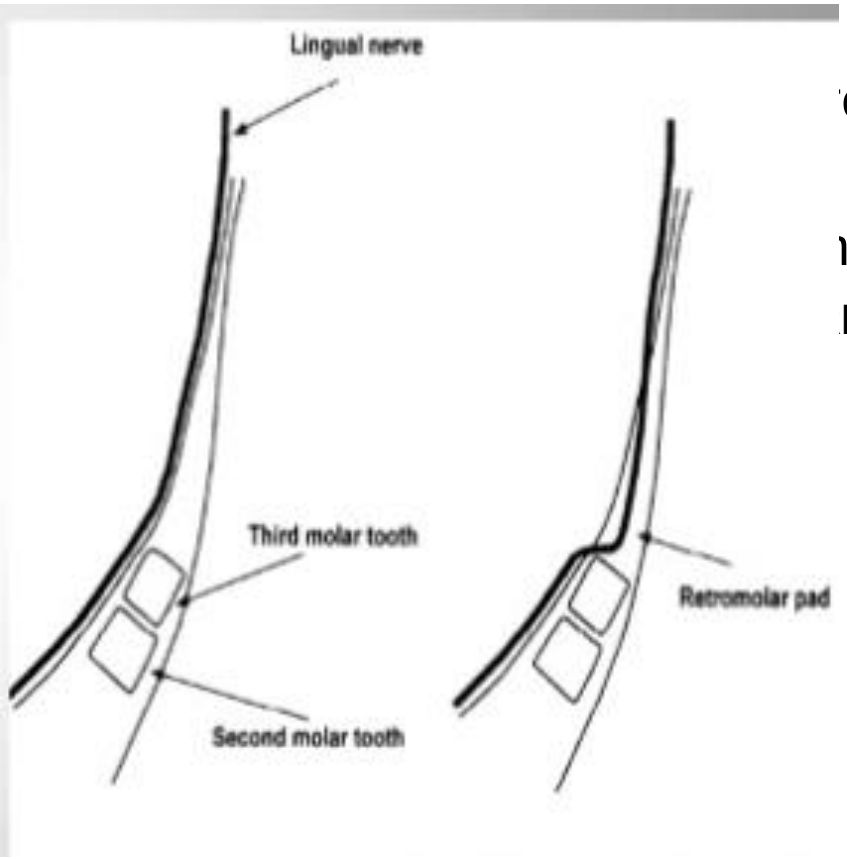

Mount Sinai Hospital
Sinai Health System
Joseph & Wolf Lebovic Health Complex

BONE REMOVAL AND TOOTH SECTIONING

- REAI
- COP

TOOTH SECTIONING AND REMOVAL MANDIBULAR THIRD MOLAR

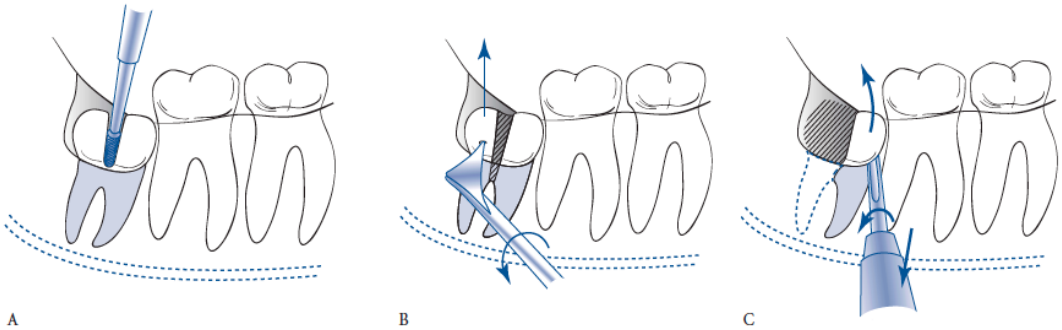

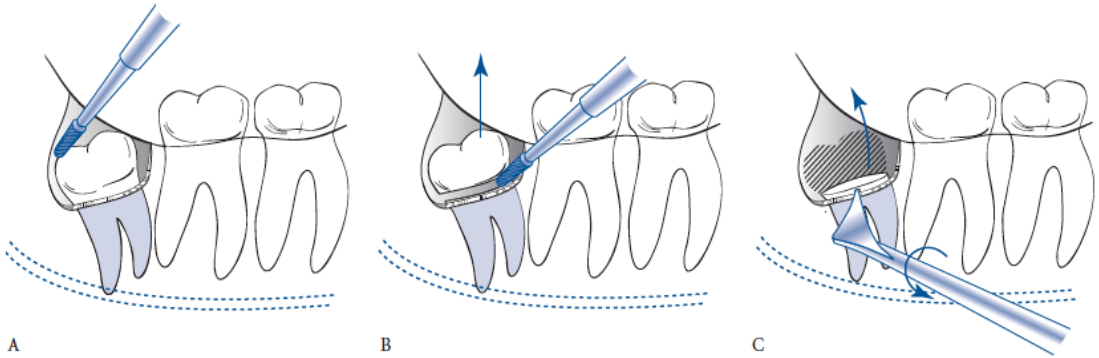

Mount Sinai Hospital
Sinai Health System
Joseph & Wolf Lebovic Health Complex

TOOTH SECTIONING AND REMOVAL MANDIBULAR THIRD MOLAR

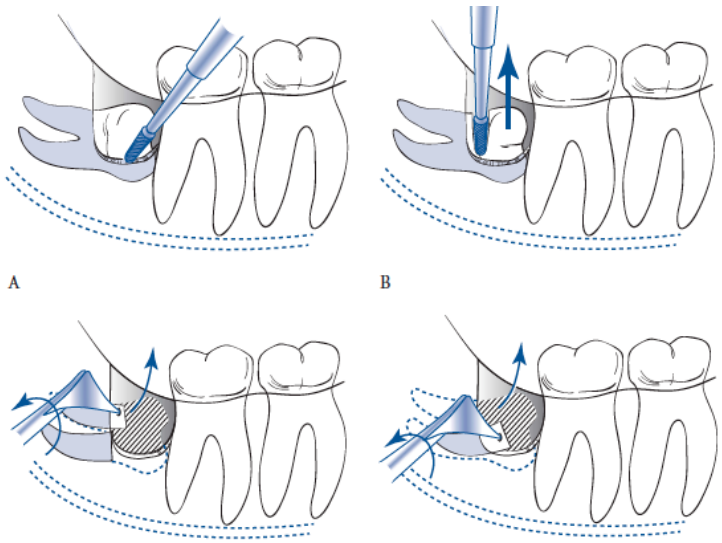

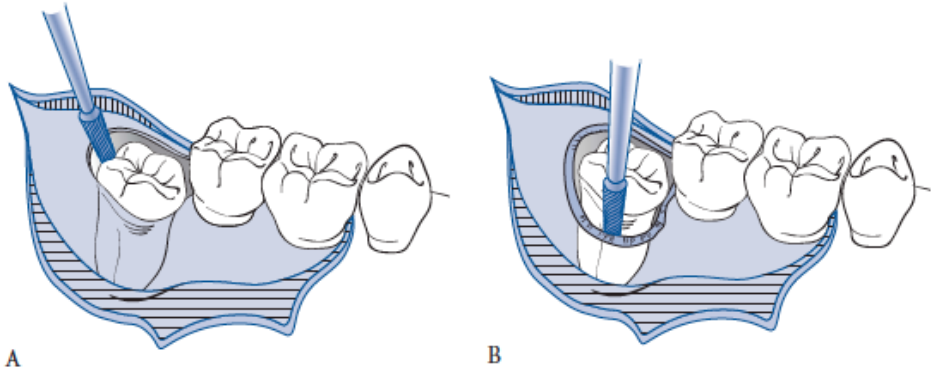

Mount Sinai Hospital
Sinai Health System
Joseph & Wolf Lebovic Health Complex

TOOTH REMOVAL
MAXILLARY THIRD MOLAR

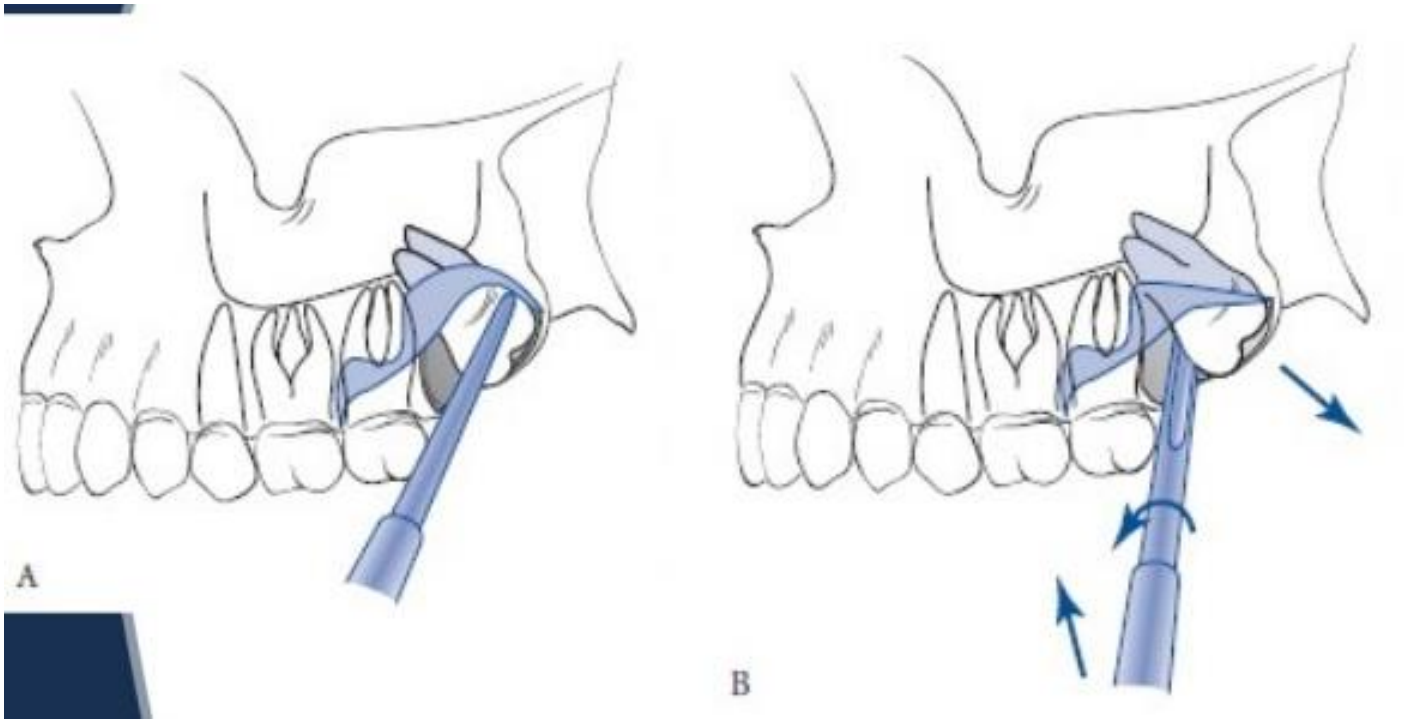

Mount Sinai Hospital
Sinai Health System
Joseph & Wolf Lebovic Health Complex

IMPACTED CUSPIDS AND SUPERNUMERARY TEETH

IMPACTED CUSPIDS AND SUPERNUMERARY TEETH

- LOCALIZE
  - Exam/palpation
  - Radiographs
    - “2 at 90”
    - CBCT

- EXTRACT VS MAINTAIN
  - Position
  - Associated pathology
  - Risk assessment for extraction

IMPACTED CUSPIDS AND SUPERNUMERARY TEETH

Mount Sinai Hospital
Sinai Health System
Joseph & Wolf Lebovic Health Complex

ALTERNATIVE TREATMENTS

ALTERNATIVE TREATMENT

- CUSPIDS
  - Localize with radiographs

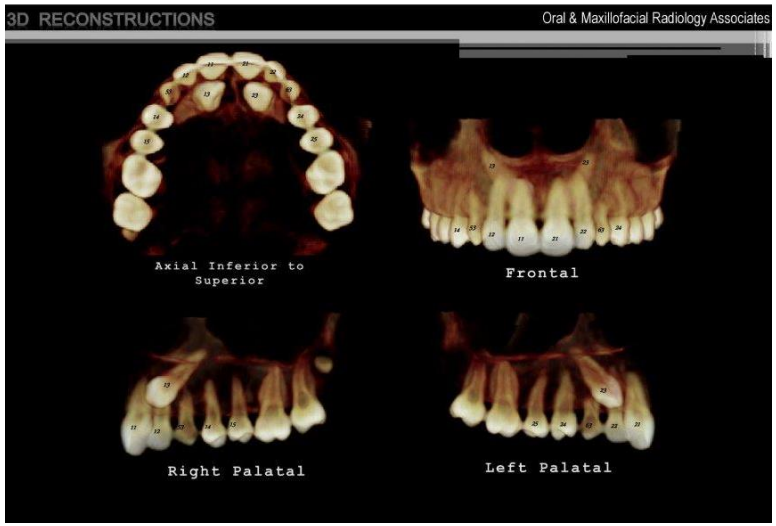

ALTERNATIVE TREATMENT

- CUSPIDS
  - Open exposure (Kokich)

  - Exposure/Bonding with orthodontic eruption

ALTERNATIVE TREATMENT

- CUSPID EXPOSURE DETERMINANTS OF SUCCESS
  - Patient age
  - Angulation of impacted cuspid
  - Space

ALTERNATIVE TREATMENT

SECOND MOLAR SURGICAL UPRIGHTING

ALTERNATIVE TREATMENT

- PARTIAL EXTRACTION (aka Coronectomy)
  - BALANCE OF RISKS
    - **Maintaining full tooth**
    - **Removing full tooth**

ALTERNATIVE TREATMENT

- PARTIAL EXTRACTION

Mount Sinai Hospital
Sinai Health System
Joseph & Wolf Lebovic Health Complex

PARTIAL EXTRACTION

- WHITE PAPER (AAOMS 2007)

"WHEN IMAGING SUGGESTS AN INTIMATE RELATIONSHIP BETWEEN THE ROOTS OF THE LOWER THIRD MOLAR AND THE IAN AND THE TOOTH STILL NEEDS TO BE REMOVED, CONSIDERATION SHOULD BE GIVEN TO CORONECTOMY WITH RETENTION OF THE PORTION OF THE ROOTS ASSOCIATED WITH THE IAN"

PARTIAL EXTRACTION

LONG TERM FOLLOW-UP REQUIRED

POST OPERATIVE INSTRUCTIONS

Mount Sinai Hospital
Sinai Health System
Joseph & Wolf Lebovic Health Complex

POST-OPERATIVE INSTRUCTIONS

- Verbally and written / link to website
  - Pressure to bleeding sockets / Tea bag
  - Ice
  - Sleep with head elevated
  - Use medications as prescribed
  - Diet
  - Contact information – **BE AVAILABLE**

CONCLUDING PEARLS

PEARLS

- Be thorough in your work-up for removal of impacted teeth
- Most impacted teeth do pose risk of infection and/or damage to adjacent teeth/structures
- If you are going to perform a procedure, make sure that you are capable of managing the complications
- Skill development requires training and practice
- Experience can not be taught

THANK YOU